



PHILIPS

Bone Suppression

Diagnostic X-ray



Philips Bone Suppression¹ delivering confidence in image interpretation

Philips Bone Suppression is an innovative image enhancement technology designed to increase the clarity of adult erect chest radiographs by suppressing bone structures on digital images.

Main benefits at a glance

- More confident image interpretation
 - Enables improved lung nodule detection up to 16.8 %²
- Fully integrated into the Eleva Workflow
 - Images are automatically added to patient files
- Uses existing chest X-rays from regular examination
 - No additional dose required
 - Immediate display on existing PACS viewer
 - No need for extra equipment
 - No additional examination times

Bone suppression technology provides radiologists with a bone-suppressed soft tissue image in addition to the conventional chest image. This supplementary image boosts diagnostic decision-making confidence without the need for additional X-ray dose or time. With bone suppression, actionable lung nodule detection is improved up to 16.8 %.²

Philips Bone Suppression is fully integrated into the Eleva workflow of the latest DigitalDiagnost C90 system. Depending on the protocol, for each adult erect chest PA/AP image a bone-suppressed image can be automatically generated. The image is then sent to PACS and can be accessed and reviewed at any time along with the conventional chest image. This is a quick and easy step to support decision-making.

“My personal feeling is that anyone reading chest films needs some type of bone suppression support”

Prof. Dr. Peter B. Sachs, MD
University of Colorado Hospital

More confident image interpretation

Philips Bone Suppression is an option to remove bone structures from chest images for an unobstructed view of soft tissue. This clear view enables a more confident image interpretation. It improves actionable lung nodule detection by up to 16.8 %², meaning a detection of 1 in 6 nodules previously missed.

“Bone Suppression” technology helps us make the correct diagnosis more quickly and confidently than ever before“

Dr. Jared Christensen, MD
Associate Professor of Radiology,
Director of the Duke University Lung Screening Program

No extra dose or steps required

Philips Bone Suppression is an algorithm that creates a bone-suppressed image automatically without the need for additional dose or effort from the user. The creation of the bone-suppressed image is done based on the existing regular chest X-ray examination and therefore does not require any additional dose.

After a standard chest X-ray image is acquired, checked and confirmed, the bone-suppressed image is generated in the background and both images are automatically sent to PACS. Both images can be read on the viewing station at any time.

“The software is easy to install, easy to train to, and, frankly it provides immediate clinical value”

Prof. Dr. Ella Kazerooni, MD, MS, University of Michigan, past president of the Society of Thoracic Radiology

Fully integrated into the Eleva workflow

The full and intelligent integration of Philips Bone Suppression software into the proven Eleva user interface, in combination with UNIQUE 2 image processing, enables confidence in image interpretation.

All of the final images are immediately and automatically sent to the PACS after completion of the examination considering they are automatically added to the patient files. There is no need for extra equipment as well as additional examination time.

Bone Suppression vs. Dual Energy Subtraction^{3,4,5}

When talking about Philips Bone Suppression it is necessary to compare it to a second technology on the market which purpose it also is to remove bone structures on chest radiographs, namely Dual Energy Subtraction (DES).

Philips is always striving for the lowest achievable dose. This approach is based on the ALARA principle (As Low As Reasonably Achievable), which is reflected in different Philips technologies such as the well-known SkyFlow Plus; the highly efficient gridless scatter radiation correction algorithm. SkyFlow Plus enables a faster, easier way of working and results in the same image impression a grid would achieve. There is less density to be penetrated and therefore less dose required. This awareness in dose also applies for the Philips Bone Suppression feature.

When comparing the methodologies of DES and Bone Suppression Imaging (BSI) a significant difference in dose saving becomes visible. While the DES is based on spectral absorption properties, which works by considering paired radiographs at different spectral energies, BSI is based on an artificial intelligence model which considers contrast and shape characteristics of bones.

DES requires the acquisition of two images to deliver results, leading to higher patient dose and the risk of motion artifacts, whereas BSI has no impact on the standard workflow. Thus for BSI, a standard X-ray system is used to acquire a standard chest examination with the standard low patient dose. This integration in the standard workflow makes the BSI highly efficient, since the bone-suppressed image is created and sent to PACS fully automatically without any additional steps for the user. In addition, a bone-suppressed image could theoretically be created retrospectively based on the standard PA/AP chest examination.

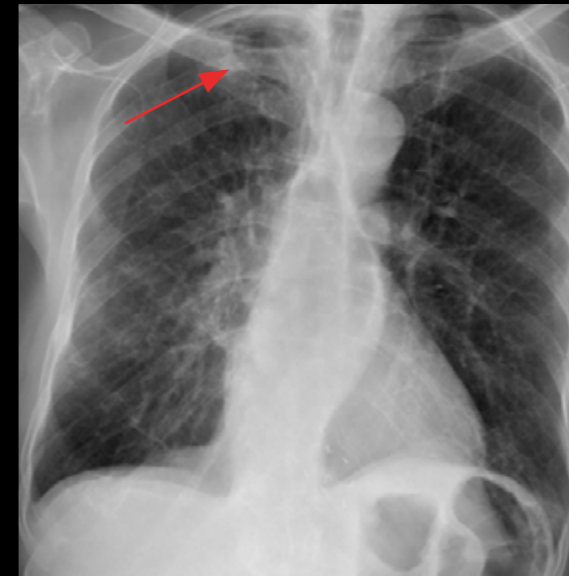
This difference in technologies has no influence on diagnostic performance.

“This would seem to be the greatest advance in interpreting chest X-rays since we went from plain film to digital imaging, which gave us better images and more control over what we were looking at”

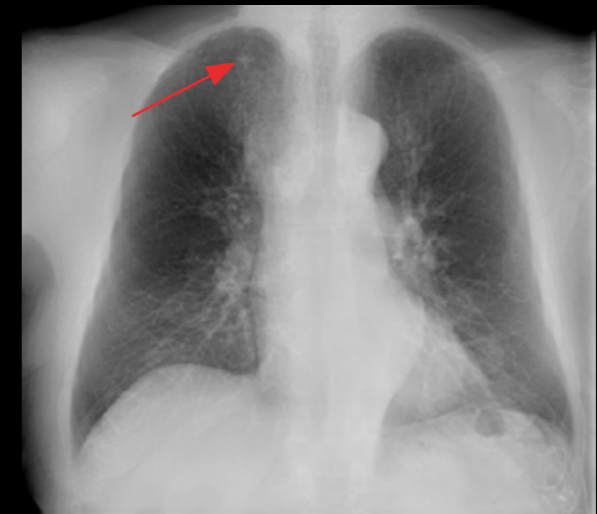
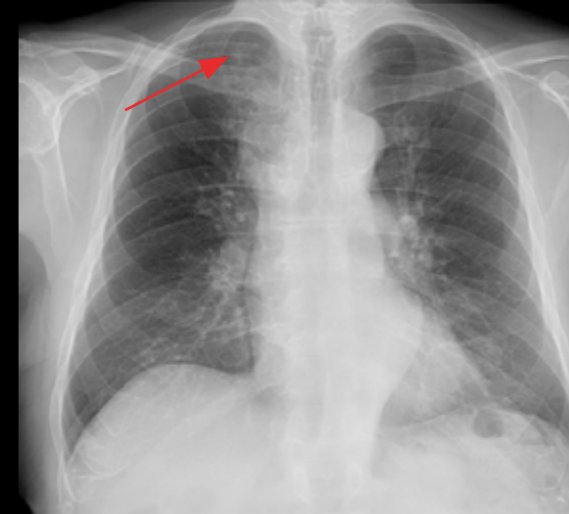
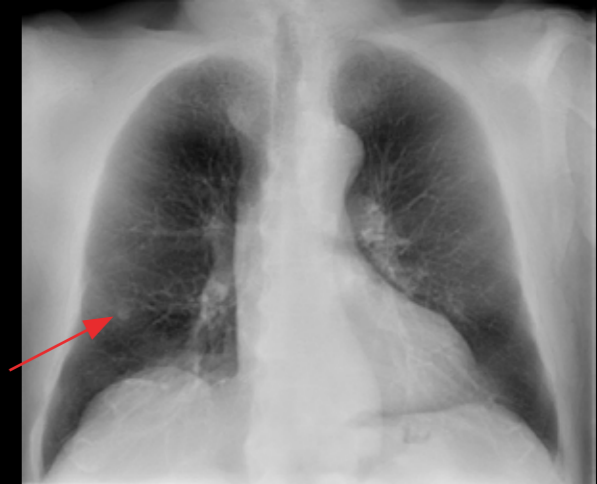
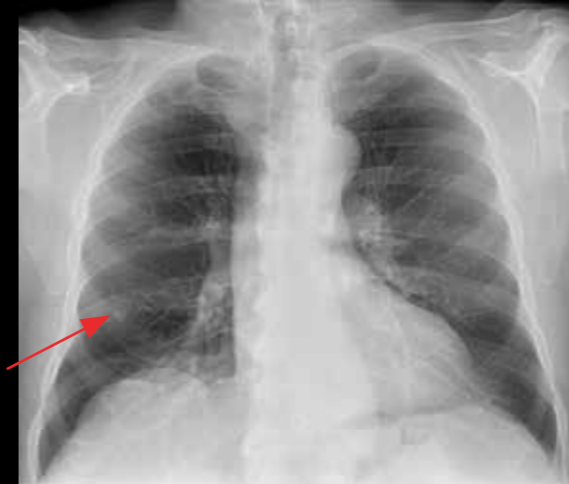
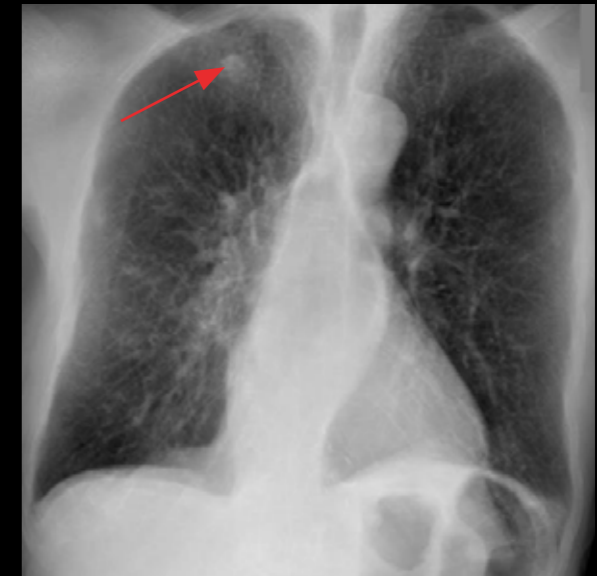
Dr. Greg Cleveland, MD
Director of Interventional Radiology at
McLeod Regional Medical Center, South Carolina

Clinical Examples

Regular Chest X-ray



Philips Bone Suppression

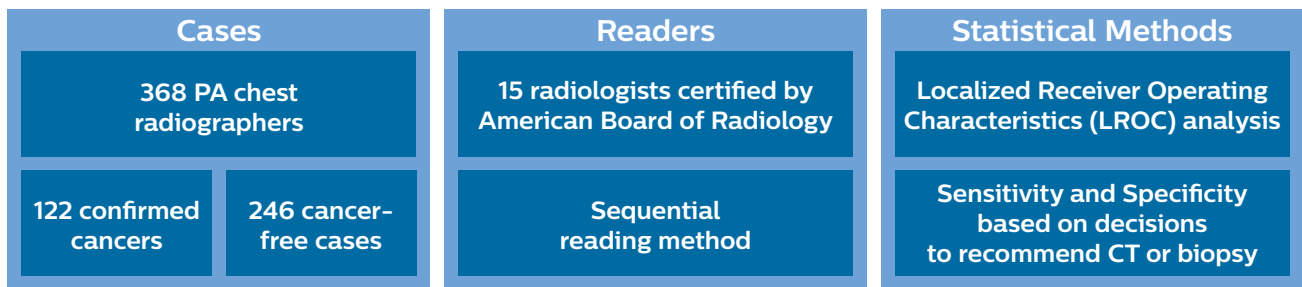


Clinical Evidence: Reader study by Freedman et al.²

According to the most prominent study on bone suppression, the study by Freedman et al., Georgetown University Medical Center, Washington D.C., a sensitivity improvement of 16.8 %² is achieved by bone suppression technology compared to standard chest examination images.

For this study the sequential reading method⁶ was employed. First, the standard or unaided image was presented to the reader. After the reader recorded the interpretation, the additional BSI image was presented on a different viewing screen, and the reader recorded a combined interpretation.

Materials and Methods



As statistical method, the “Localized Receiver Operating Characteristic” (LROC) analysis was employed. Hence, not only the correct decision on the presence of nodule was analyzed, but also the correct position of the nodule in the image.

The result of this was that the Area Under Curve (AUC) increased significantly (confidence measure $P < 0.05$) as figure 1 indicates. More practically speaking this means: Sensitivity of BSI increased by 16.8 %² vs. unaided (see figure 2). However, a slight decrease in specificity has been observed: This slight increase in false positive findings is in the typical range that has also been reported for DES (see figure 3).

Result: Readers detected 1 out of 6 previously missed nodules using Bone Suppression.

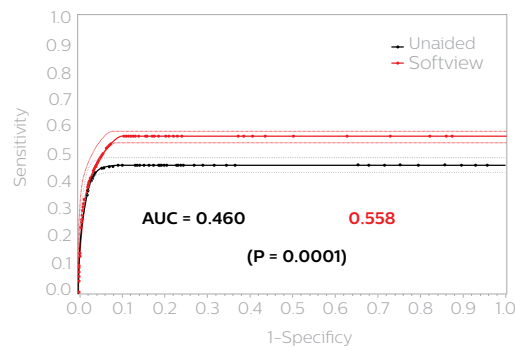


Figure 1²: Aggregate LROC for Unaided vs. Bone Suppression

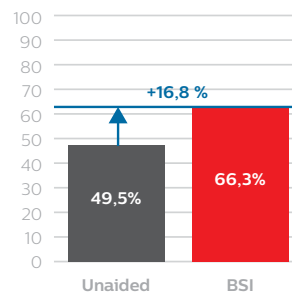


Figure 2: Sensitivity (%)

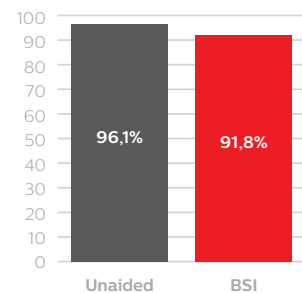


Figure 3: Specificity (%)

¹ ClearRead Bone Suppression by Riverain Technologies

² Freedman M et al. Improved detection of lung nodules with novel software that suppresses the rib and clavicle shadows on chest radiographs. Radiology. 2011, July, 260(1): 265-275. After publication of the actual study the product was renamed from Softview to Bone Suppression Imaging.

³ Li F, MacMahon H, et al. Small lung cancers: Improved detection by use of bone suppression imaging - Comparison with dual-energy subtraction chest radiography. Radiology. 2011 Dec; 261(3):937-949

⁴ Novak RD, et al. A comparison of computer-aided detection (CAD) effectiveness in pulmonary nodule identification using different methods of bone suppression [...]. J Digit Imaging. 2013 Jan; 26: 651-656

⁵ Szucs-Farkas Z, et al. Comparison of dual-energy subtraction and electronic bone suppression combined with computer-aided detection [...]. AJR Am J Roentgenol. 2013 May; 200(5): 1006-1013

⁶ Kobayashi T, Xu XW, MacMahon H, Metz CE, Doi K. Effect of a computer-aided diagnosis scheme on radiologists' performance in detection of lung nodules on radiographs. Radiology 1996; 199(3): 843-848, An alternative method would have been to have an independent read of just the standard images at least 30 days before the sequential read.

